

Background:

Equine sarcoids (Fig. 1) are probably the most common manifestations of cutaneous tumors in horses and it's phylogenetic relatives.

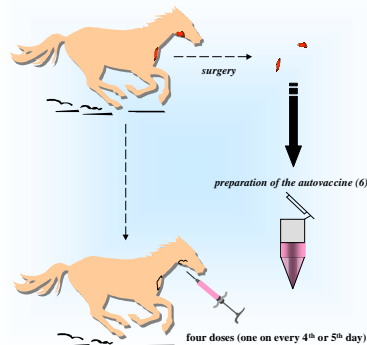
It is discussed that equine papilloma virus is the causative agent of this in most cases benign tumor (1). However, treatment is complicated by a high rate of relapse after surgery. After carbon dioxide laser surgery the rate of relapse was reported to be 38% (2). Because of that high rate of recurrence a great variety of post-operative preventative treatments have been proposed. These proposals include non specific treatment using emulsified BCG (*Mycobacterium tuberculosis* Bacillus Calmette Guerin, see Ref. 3) or other nonspecific immune stimulating preparations. However, the success and usefulness of those methods is subject of controversy debate (4). Another method of treatment is the use of tumor material to stimulate the immune system specifically (5). Basing on our experience in using autovaccination to treat various forms of infectious diseases in humans (see for instance Poster 1, this conference) and animals (see also talk S40, this conference), we started to evaluate patient specific autovaccination (Fig. 2) for the prevention of post-operative recurrent sarcoids.

Fig. 1: Typical manifestation of equine sarcoid. The size and location of the sarcoids may vary, also multiple sarcoids have been observed. The tumor is normally removed by surgery and the horses are treated with various methods to prevent the highly common relapses.

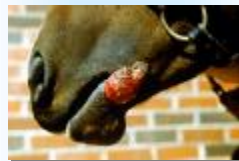

Image with kind permission of Dr. Gregory A. Campbell, Veterinary Medicine, Oklahoma State University <http://web.cvm.okstate.edu/photographs/images/cvca0239.jpg>

Fig. 2: Autovaccination against recurrent sarcoids in horses.

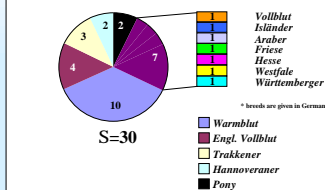


Methods:

During the last 4 years 51 horses were autovaccinated to prevent recurrence of equine sarcoids after surgery (see Fig. 1). In December 1999 we sent out questionnaires to the treating veterinarians asking for anamnestic details of the animals treated with our autovaccine. The response covered some 30 horses for which data could be evaluated on a retrospective basis. The horses were of different breeds as shown in Fig. 3.

The mean age of these horses (15 male /15 female) was 7.83 +/- 0.76 years (Fig. 4, red bar). The mean observation time between the start of autovaccination and sending out the questionnaire was 15.133 +/- 1.57 month (Fig. 4, blue bar). From six randomly chosen horses blood samples were obtained during autovaccination and analyzed by flow cytometry for the percentage of CD4+, CD8+ and CD21+ positive cells within the lymphocyte population. The results are given in Fig. 7.

Fig. 3: Distribution of breeds* within the autovaccinated horses.



Therapeutic vaccines in the treatment of equine papilloma virus infection

Results:

26 out of 31* horses (87.1%, Fig. 6) showed no further relapse in the time between completion of autovaccine and Dec. 99 when the data were requested. The mean time of being free of relapse was 14.69 +/- 1.682 month (Fig. 4, green bar), differing not significantly from the mean observation time for all animals.

21 of the horses were autovaccinated after a primary sarcoid was removed, the remainder, being 10 horses, were autovaccinated after recurrent sarcoids were observed. 18 of the 21 did not develop relapses which was true for 8 of the 10. The mean time without relapse appears to be longer in the group of animals vaccinated after primary sarcoids had been removed (Fig. 5). This difference, however is not significant.

* one was vaccinated twice

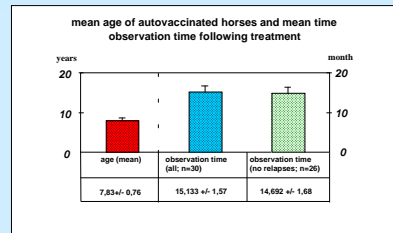


Fig. 4: The mean age (in years +/- S.E.) is given as well as the time in month (+/- S.E.) between autovaccination and sending out the questionnaire. The blue bar gives the observation time for 30 horses, the green bar gives the observation time only for those animals which showed no relapse following autovaccination. There was no correlation between relapse and observation time.

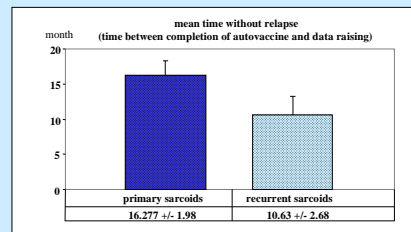


Fig. 5: The mean time in month (+/- S.E.) between completion of autovaccination and Dec. 99 (date of requesting the data). The dark blue bar gives the observation time for 18 horses which were vaccinated after removal of primary sarcoids, the light blue bar gives the time for those animals to which the autovaccine was administered after relapses were already observed.

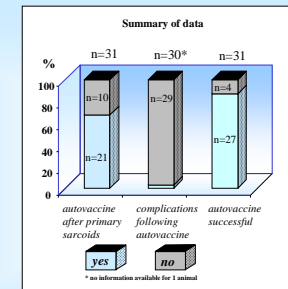
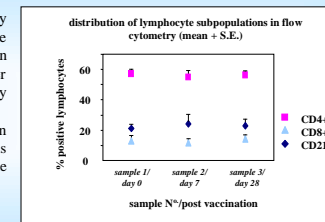


Fig. 6: Summary of the data concerning the 30 horses (one was autovaccinated twice).

Fig. 7: Results obtained by flow cytometry of whole blood samples drawn on prior to (day 0) and after start of autovaccination (day 7 and day 28; n=6 horses). No differences in the mean lymphocyte sub-populations were observed during the course of autovaccination.



Conclusions:

Autovaccination for prevention of recurrent equine sarcoids, which are normally observed quite often following surgery, seems to be a useful method of treatment. The rate of recurrence was 12.9 % when our autovaccine was used for prevention, thus being much lower than reported previously (2). However, a long time observation is necessary to evaluate the actual success rate of this methodology. Although there is no significant difference in the time without relapse between those animals vaccinated after primary and after recurrent sarcoids, long term studies are necessary to examine whether primary or secondary sarcoids are of influence concerning efficacy of autovaccination.

Analysis of changes in the lymphocyte sub-populations in the blood of six horses during the course of autovaccination revealed no differences. The immunological background of the functioning of autovaccines therefor remains unknown. The autovaccine in general seems to be safe (because only material is used which is already recognized by the immune system). However, one of the horses in this study was reported to have shown adverse reaction (i.e. shock). The reason for this is hitherto unknown, the phenomena must be taken into account when using autovaccines. However, out of several thousand animals autovaccinated against a variety of micro-organisms and diseases throughout the last years, this was the first report of serious adverse effects.

References:

- Goodrich et al (1998): Equine Practice 14(3):607-623
- Carstensen et al (1997): Canadian Veterinary Journal 38(12):773-776
- Klein (1990): Tijdschrift voor Diergeneeskunde 115(24):1149-1155
- Studer et al (1997): Schweizer Archiv für Tierheilkunde 139(9):385-391
- Tallberg et al (1994): Deutsche Zeitschrift für Onkologie 26:34-40
- patent pending PCT/EP/DE